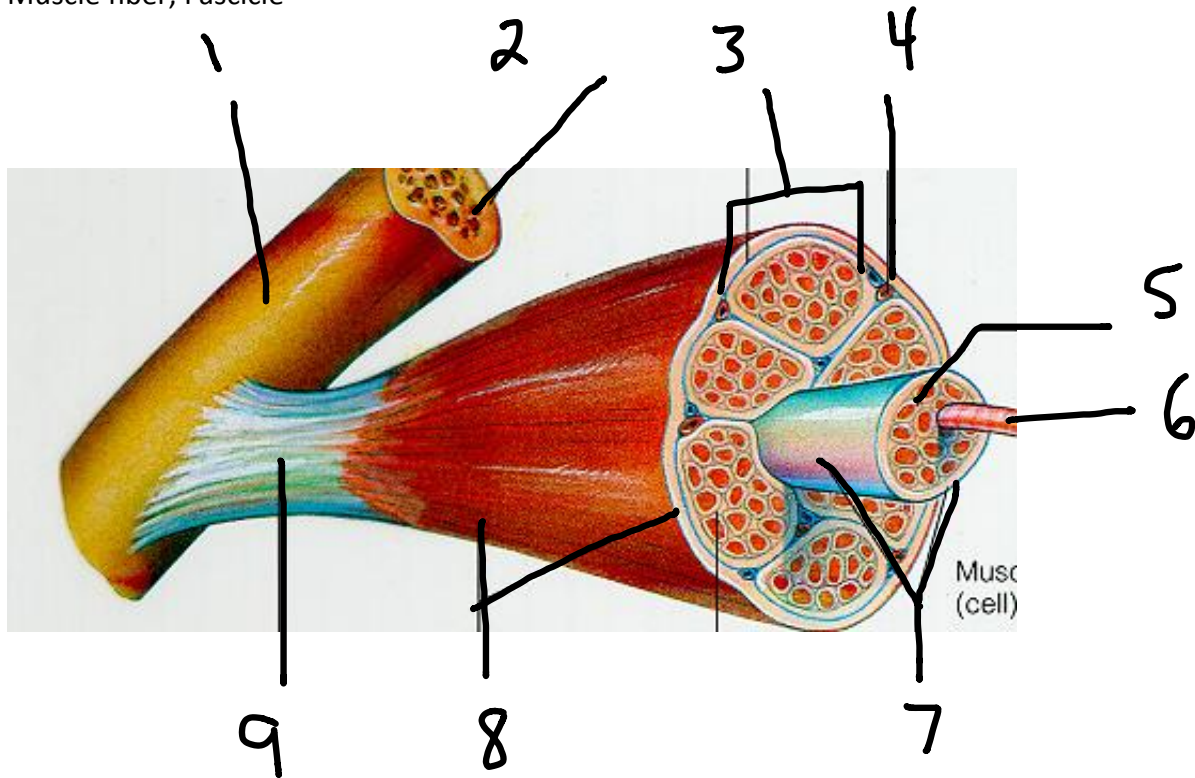


Muscular System Diagrams

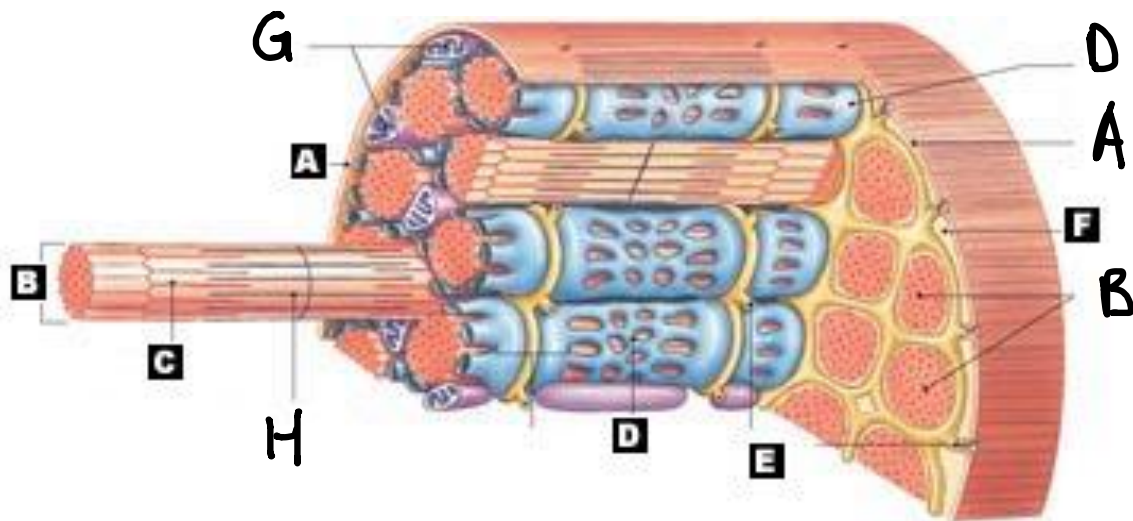
Single Muscle Belly and Membranes

Word Bank: Epimysium, Perimysium, Endomysium, Bone, Periosteum, Tendon, Blood vessels, Muscle fiber, Fascicle

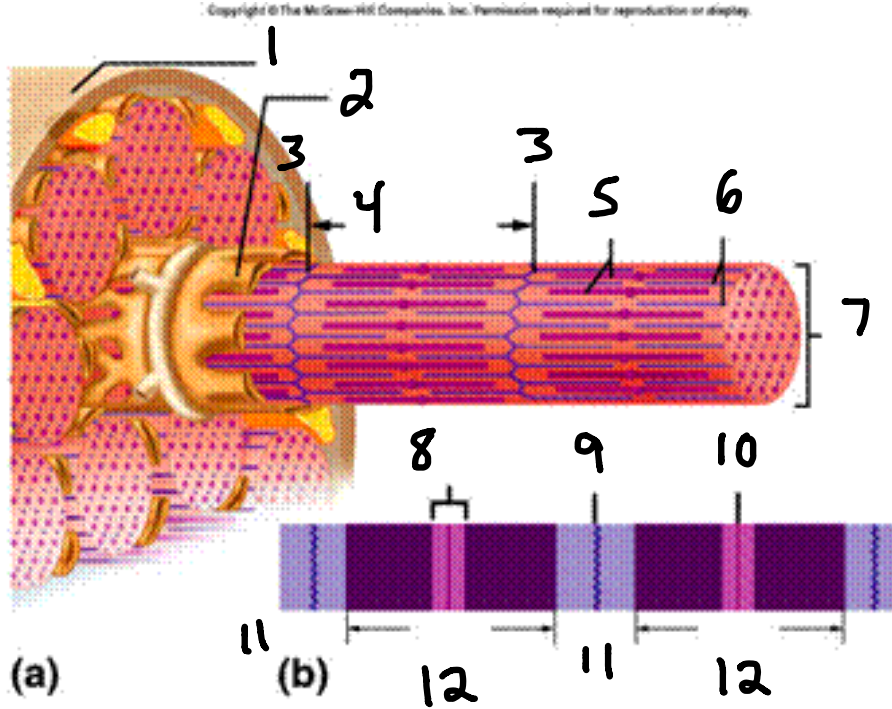


Muscle Fiber Structure

Word Bank: Sarcolemma, Sarcoplasm, Myofibril, Thick/Myosin, Thin/Actin, Mitochondria, Sarcolemmic reticulum, T-tubules



Word Bank: Sacromere, H zone, A band, I band, Z line, M line, Myofibril, Sarcolemma, Sacroplasmic reticulum, Myosin, Actin



Sarcomere Structure

Work Bank: Sarcomere, Actin, Myosin, H zone, Z line, M line, A band, I band

