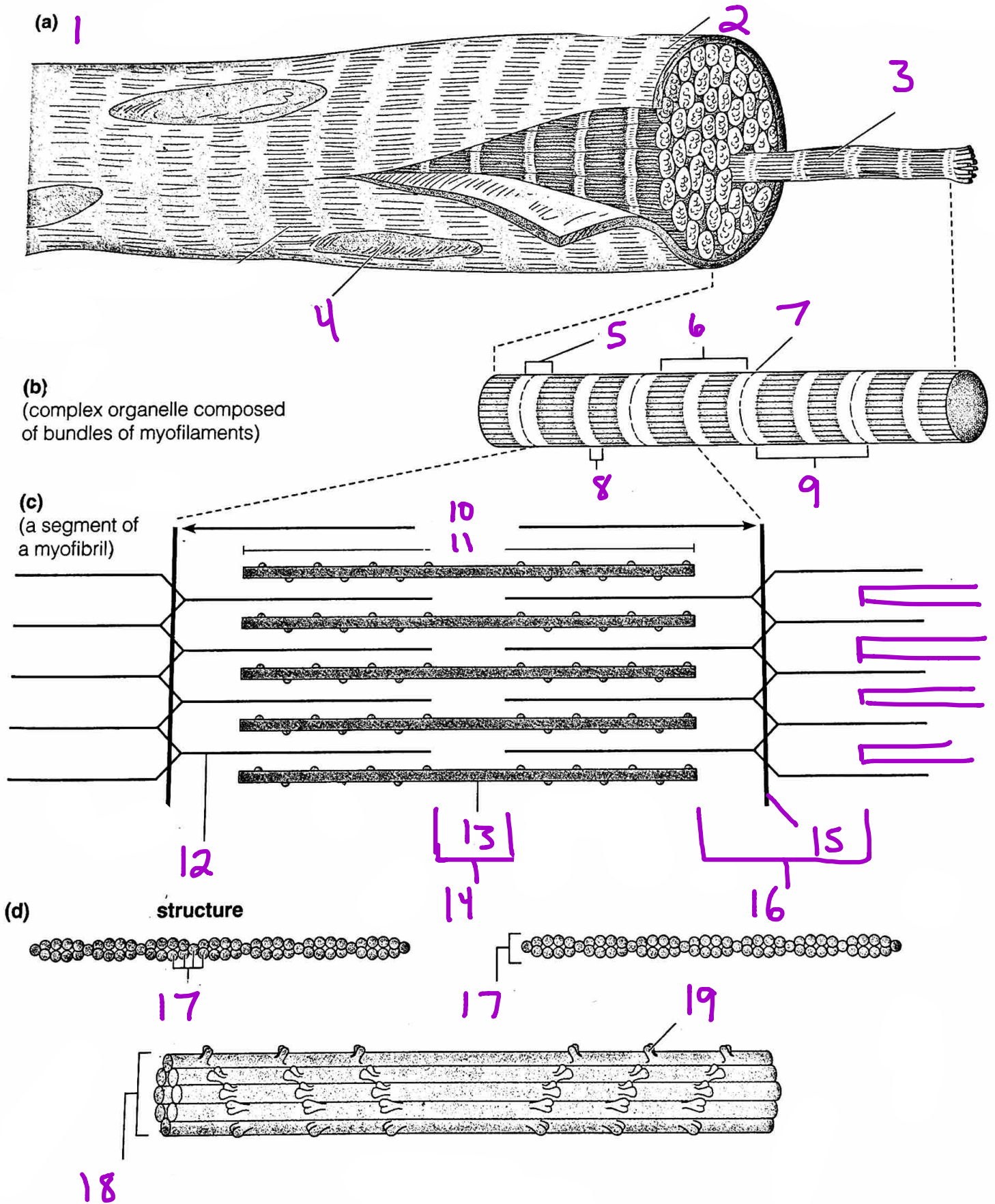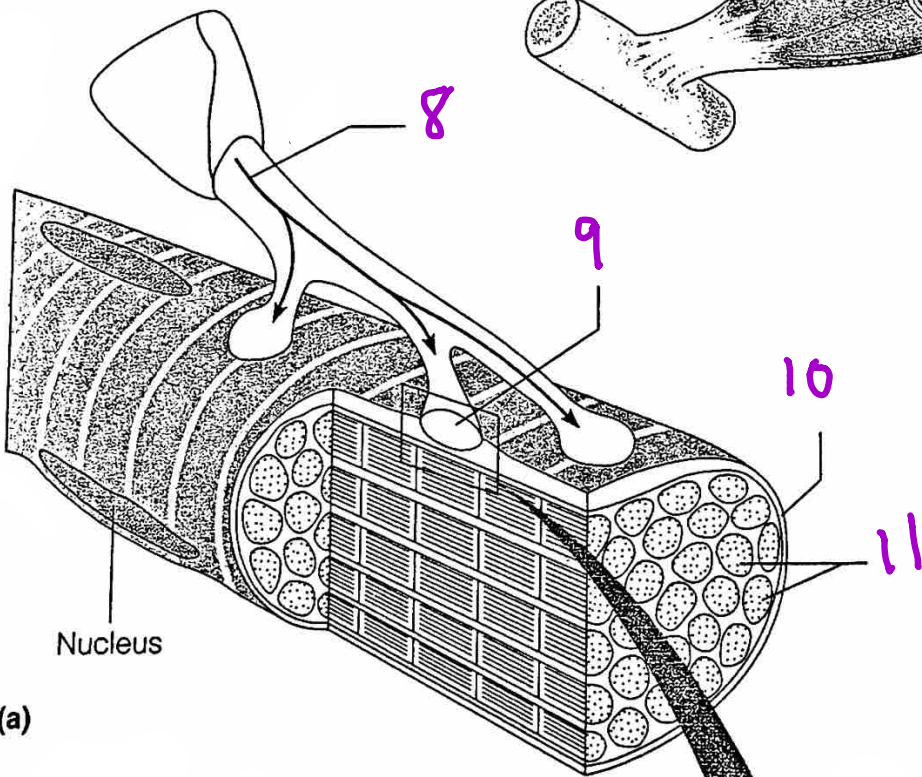
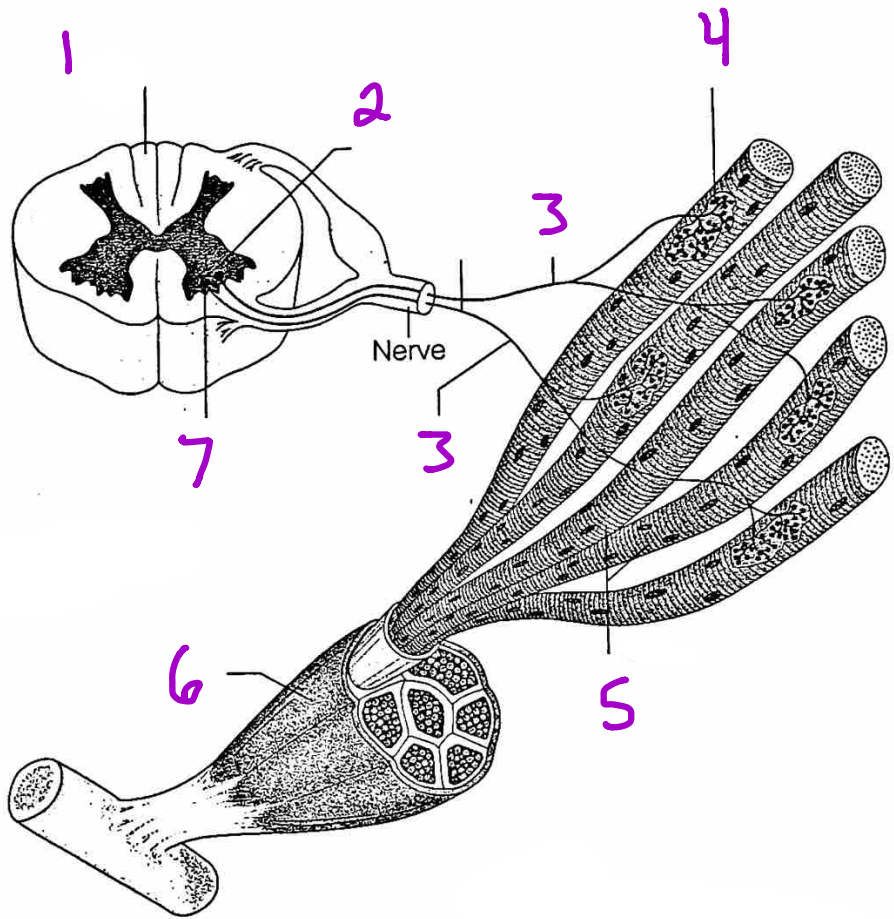


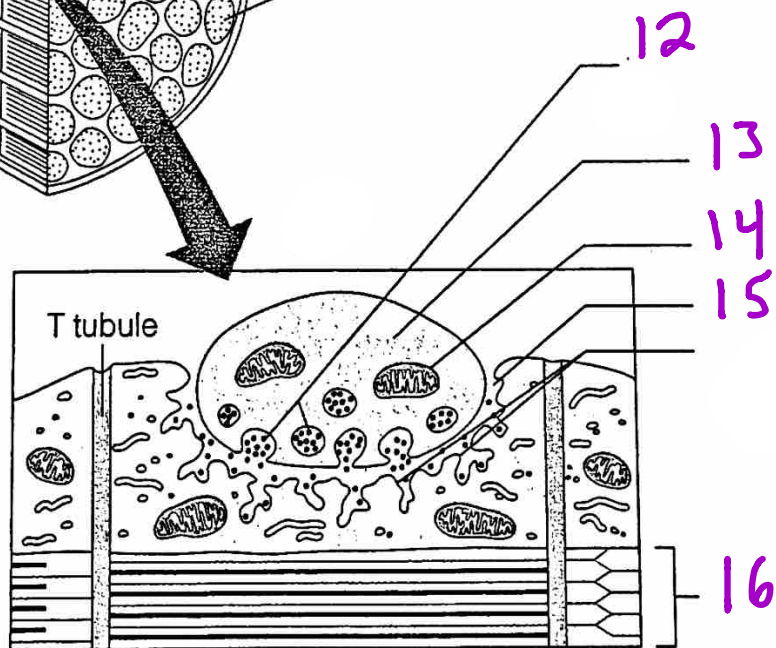
Figure 6.3 Anatomy of a skeletal muscle cell (fiber). (a) A portion of a muscle fiber. One myofibril has been extended. (b) Enlarged view of a myofibril showing its banding pattern. (c) Enlarged view of one sarcomere (contractile unit) of a myofibril. (d) Structure of the thick and thin myofilaments found in the sarcomeres.

Muscle Contraction

Motor Unit



Neuromuscular Junction



(b)

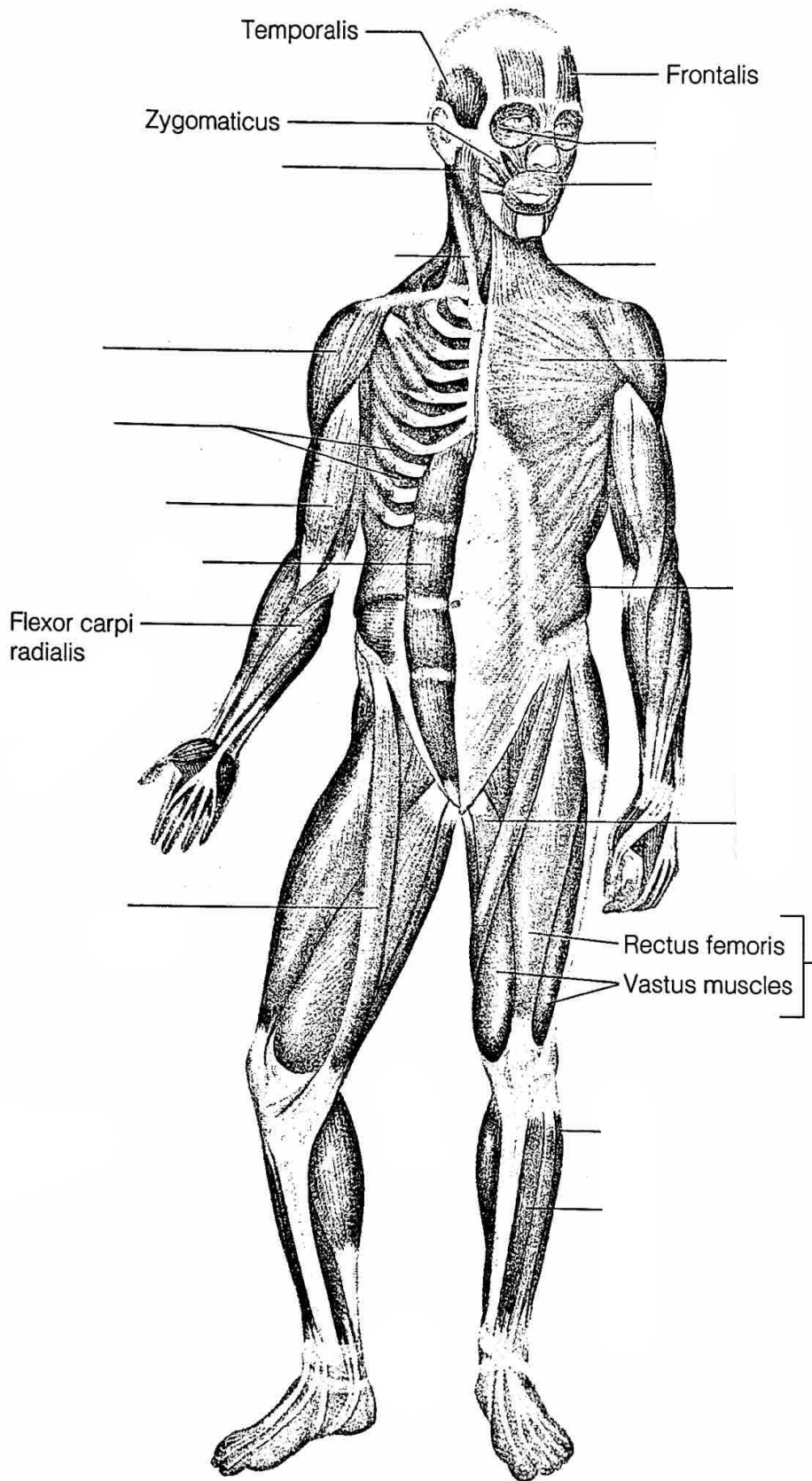


Figure 6.20 Major superficial muscles of the anterior surface of the body.

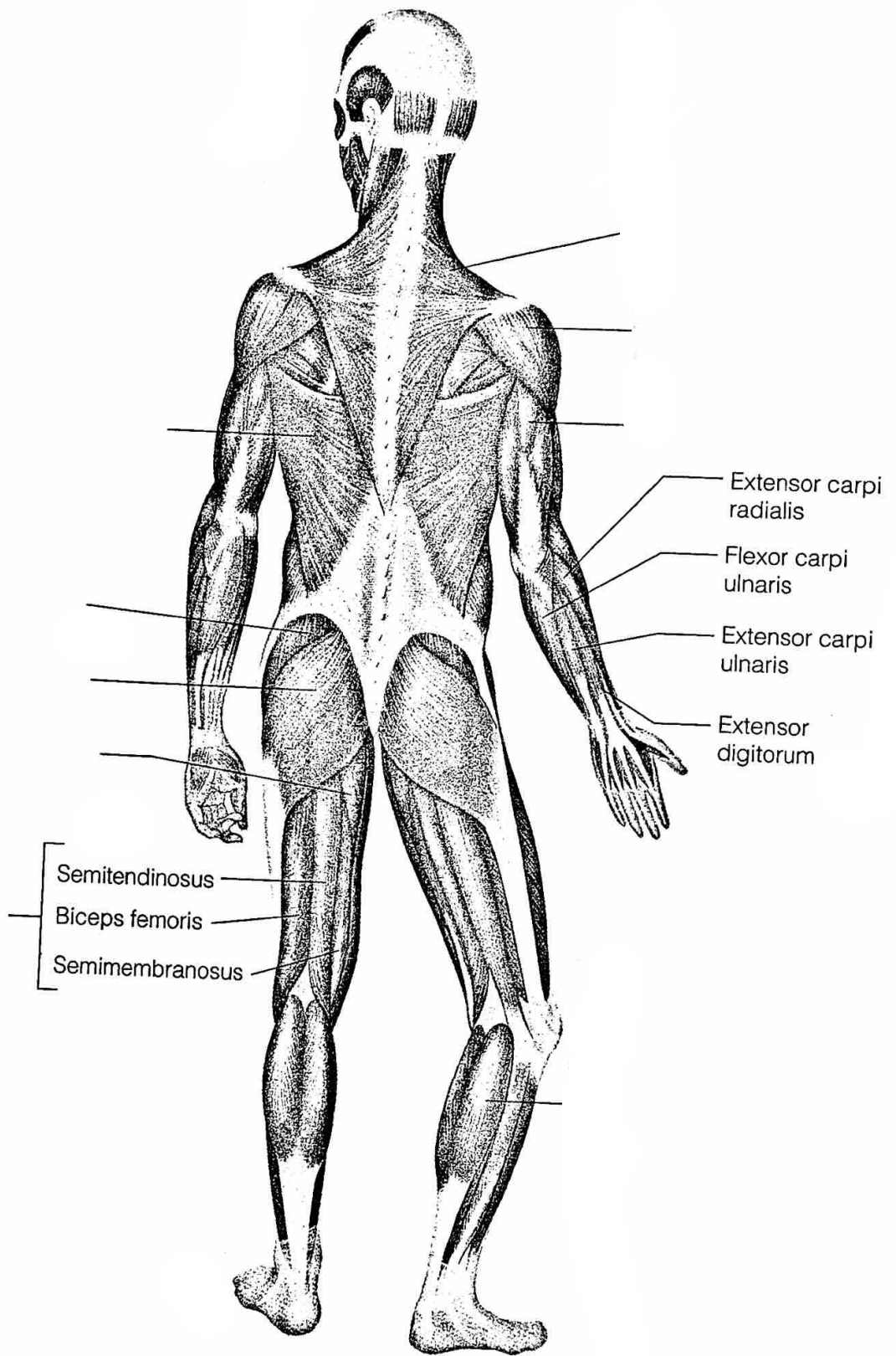


Figure 6.21 Major superficial muscles of the posterior surface of the body.